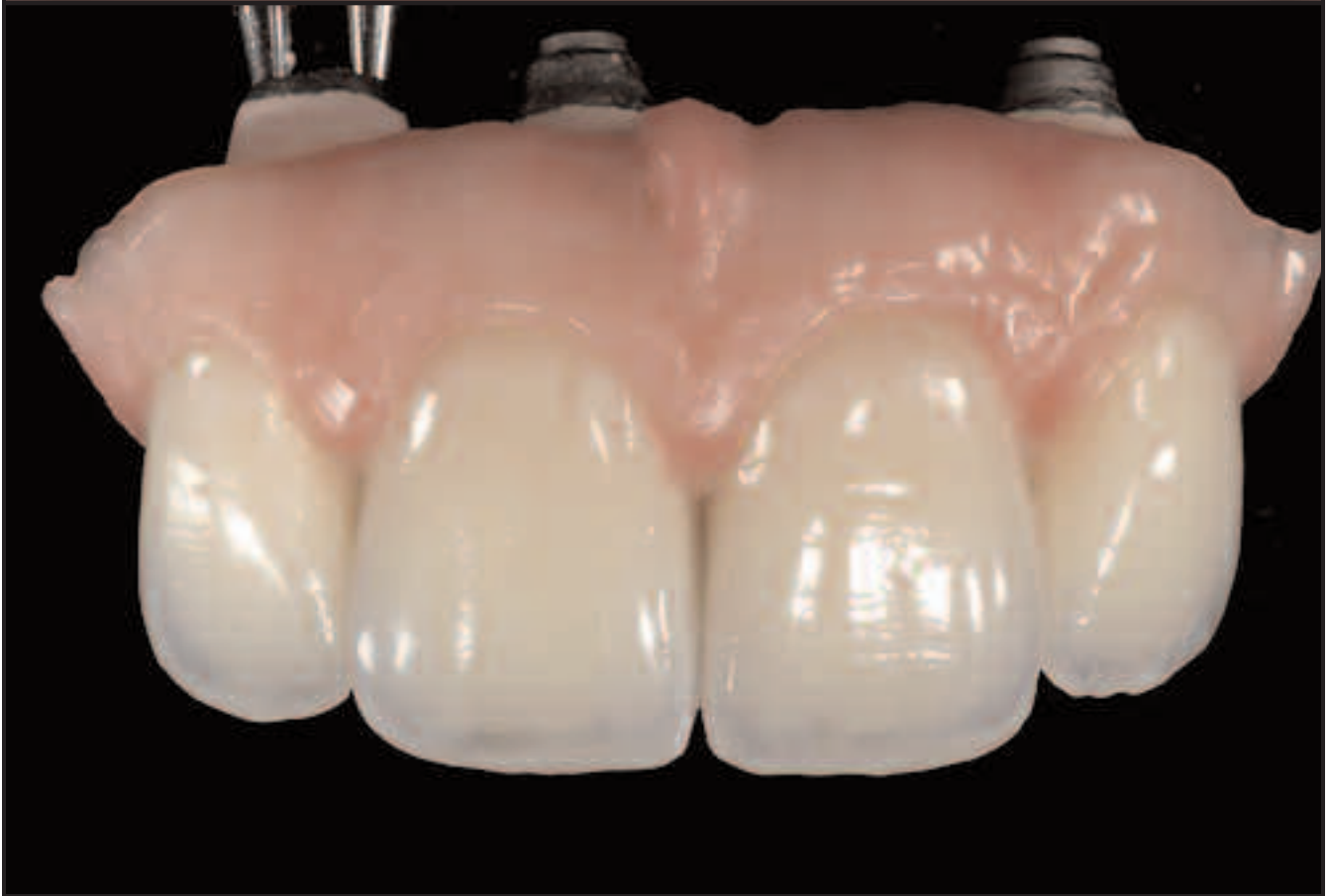
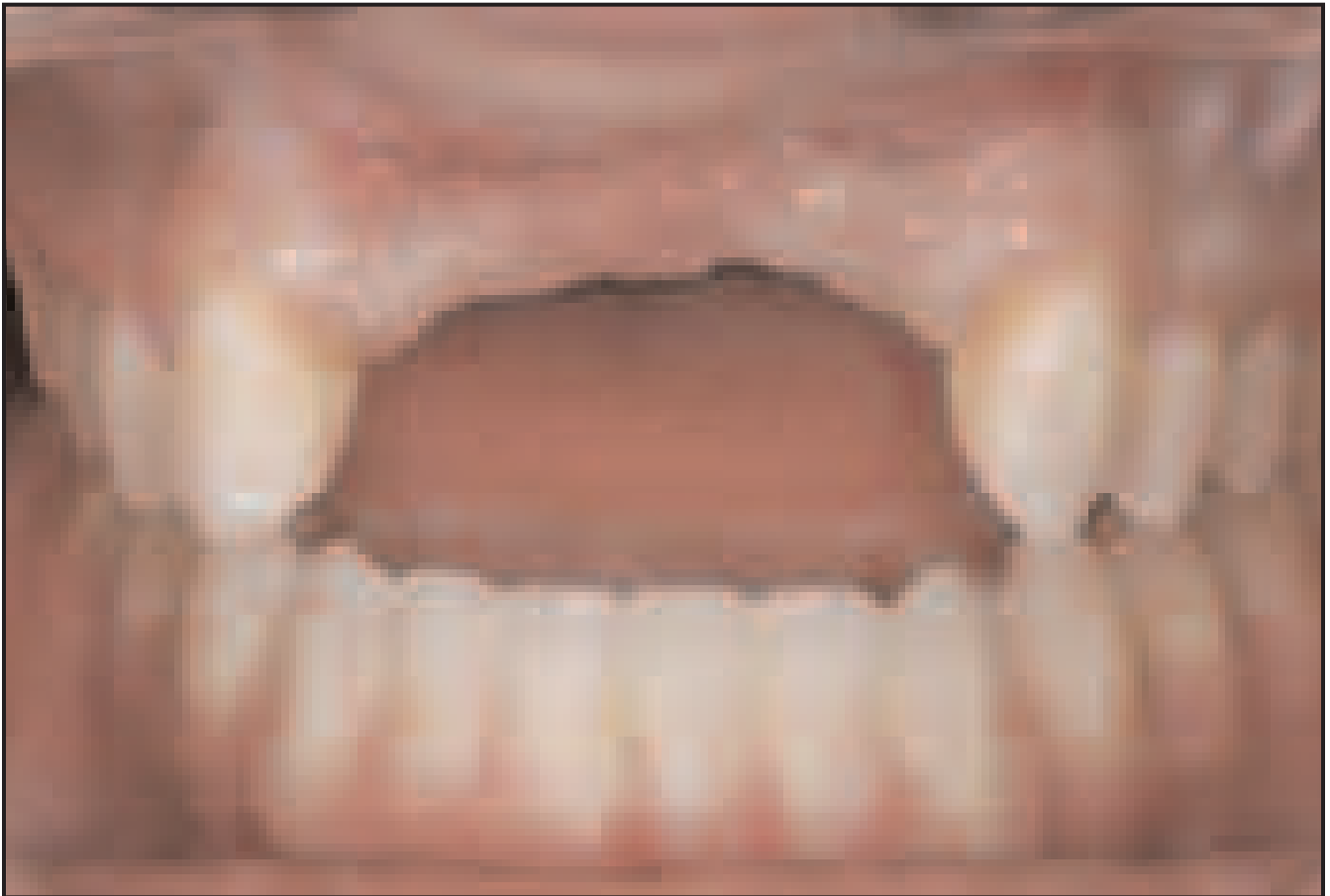
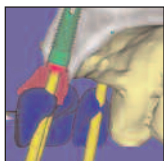

Prosthetic Gingival Reconstruction in the Fixed Partial Restoration. Part 2: Diagnosis and Treatment Planning



Christian Coachman, DDS, CDT¹/Maurice Salama, DMD²/
David Garber, DMD³/Marcelo Calamita, DDS⁴/
Henry Salama, DMD²/Guilherme Cabral, DDS, CDT¹

[AU: No abstract was included with your manuscript. Please read what has been provided and make any necessary changes.] This second article in a three-part series on the use of artificial gingiva in fixed partial restorations focuses on diagnosis and treatment planning. Often, traditional treatment of complicated situations can result in a definitive restoration that is less than esthetic. With appropriate planning that incorporates thorough clinical examinations, three-dimensional imaging, diagnostic wax-ups, and consideration of patient expectations, a modified approach to ridge augmentation, implant placement, and prosthetic reconstruction can lead to an ideal restoration that incorporates artificial gingiva. (Int J Periodontics Restorative Dent 2009;29:xxx-xxx.)

*Ceramist, Team Atlanta Lab, Atlanta, Georgia.

**Clinical Assistant Professor, Department of Periodontics, University of Pennsylvania, Philadelphia, Pennsylvania; Medical College of Georgia; Private Practice, Atlanta, Georgia.

***Clinical Assistant Professor, Department of Periodontics, University of Pennsylvania, Philadelphia, Pennsylvania; Private Practice, Atlanta, Georgia.

****Associate Professor of Removable Prosthodontics, Guaralhos University of São Paulo, São Paulo, Brazil; Private Practice, São Paulo, Brazil.

Correspondence to: [\[AU: please provide contact information.\]](#)

Site development procedures¹⁻³ have been studied and used during the past 20 years in an attempt to correct many complex deformities of the anterior arch, but success is often elusive. Even when all the established parameters for diagnosis and treatment planning are respected⁴⁻⁶ and performed with skill, the dental team and the patient can find themselves dissatisfied with the final esthetic result.

Often, after bone and soft tissue grafts are performed, followed by tissue conditioning, the patient is sent to the technician for finalization. The technician must try to restore prosthetically the anatomy that could not be completely reconstructed surgically.^{7,8} The definitive restoration, despite the technician's effort in relation to functional and esthetic goals, can be considered a failure and generate frustration, as it differs from the previously determined objectives and the patient's own expectations. Failures in this arena are often not technical but, in fact, diagnostic in nature, as the biologic response of the host tissues to the surgical procedures is unpredictable and is not completely taken into consideration.

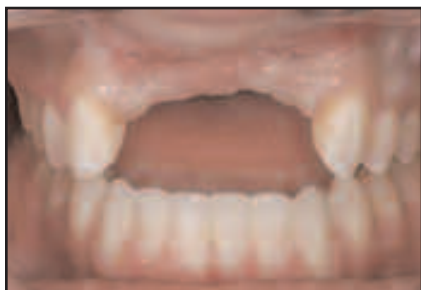

Fig 1 Preoperative situation.

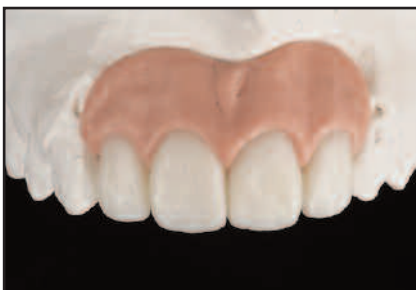

Fig 2 Dental gingival diagnostic wax-up over study model. Ideal tooth proportions and gingiva are established.

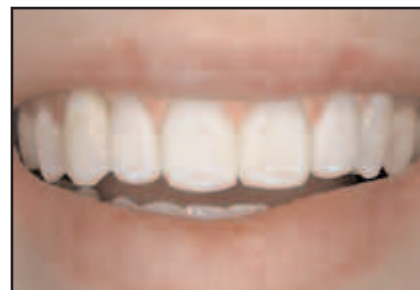

Fig 3 Wax-up try-in in patient's mouth. Notice that the transition between artificial and natural gingiva occurs outside the lip perimeter when smiling.

In many instances, regenerative surgeries are not the most ideal option because of biologic and emotional reasons, in addition to the high cost and longer treatment time.⁹ Therefore, the authors recommend that clinicians plan to include artificial gingiva in the prosthetic reconstruction.

Diagnosis and treatment plan for artificial gingival reconstruction

First appointment

The first appointment should include a comprehensive clinical exam. This should incorporate a clinical examination (Fig 1), impressions for study models, bite registration, photographs, and recording of the patient's dental ("white") and gingival ("pink") structures, with special attention paid to the expectations of the patient.^{7,8} An initial discussion must take place about the many treatment possibilities, including prosthetic gingival reconstruction.

Dental gingival diagnostic wax-up

The diagnostic wax-up is critical for the reconstructive team, as it helps to define the indications and limitations of surgical techniques or prosthetic procedures (Figs 2 and 3). Moreover, it has several other functions: (1) it provides data that are needed to create accurate radiographic and surgical stents; (2) it provides a matrix for fabrication of a provisional restoration; (3) it provides a blueprint for the dental positioning and adjustment of the axes of teeth, with the try-in serving as an esthetic plan for the interchange between the patient's own remaining gingiva and ridge contour and that of the artificial gingiva to occur outside the lip perimeter (Fig 3); and (4) it determines the design of the framework (ie, how much ceramic support and cervical extension are necessary).

The dental-gingival wax-up should seek the ideal position of teeth, without reference to the current position of the alveolar ridge. For the latter, the technician should use all the informa-

tion obtained at the first appointment. Principles of teeth setting for dentures, such as the ideal distance between the incisive papilla and the buccal surface of the central incisors (7 to 8 mm), are important guidelines to incorporate.¹²

When analyzing the preoperative study models and wax-up, the amount of pink wax will indicate clearly the amount of tissue that has been lost in all three dimensions. This will establish the prognosis for the surgical techniques that might be necessary to reconstitute ideal ridge and gingival form. This allows for a more realistic discussion with the surgeons involved regarding the volume of bone and tissue necessary for a successful outcome. Diagnostic mistakes occur in a large number of patients that were not planned for artificial gingiva, but end up with this kind of restoration (a prosthetic gingival "patch"), which limits the esthetic result.

If planning is poor, complications can occur later in the treatment process. Some of the challenging issues that can be found in these situations are:

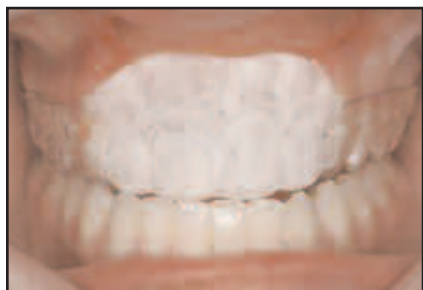

Fig 4 Radiographic stent generated from the diagnostic wax-up.

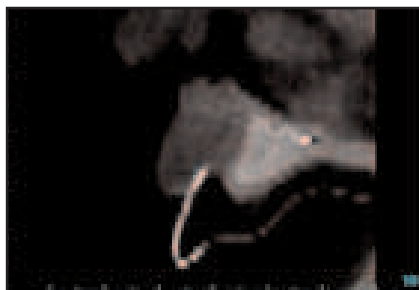


Fig 5 Image obtained from the CT scan, with the stent outlined in radiopaque material.

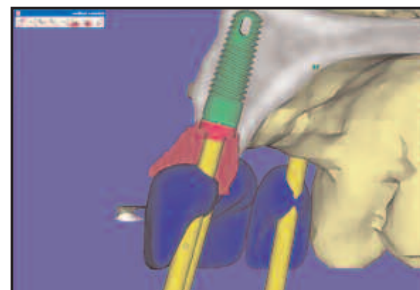


Fig 6 Virtual implant placement planning with 3D simulation software.

- The interface between artificial and natural gingiva is visible in the esthetic zone.
- The depth of implants is insufficient to provide an adequate emergence profile, sometimes necessitating a forced buccal cantilever or ridge overlap design.
- Lingual screw access is impossible, making a screw-retained restoration unfeasible and limiting retrievability.
- More implants are placed than necessary; this can make it hard to explain later on to the patient why all the implants placed originally are not restored.
- The ridge shape is inappropriate to receive the artificial gingiva.

At this stage of treatment, the room for significant alterations is restricted and the artificial gingival reconstruction becomes an enormous challenge for the lab and ceramist.




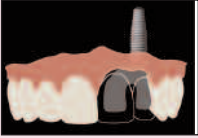



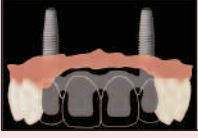

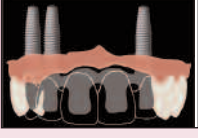

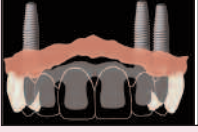
Computed tomographic scan and initial planning

Computed tomographic (CT) scans should be performed. With the radiographic stent created from the diagnostic wax-up (Fig 4), one can then evaluate, with three-dimensional (3D) simulation software, the 3D positions of implants that are needed and the number of implants required (Figs 5 and 6).

The positions of the implants in the arch, the number of implants, and their inclination and depth are specific for prosthetic gingival restorations and can be determined on the computer screen.¹³ With 3D simulation software (Simplant 11.0, Materialise), the implant team can plan the implant locations precisely according to the ideal teeth and gingival positions shown on the radiographic stent. Each site and patient should be analyzed individually, because sometimes the ideal esthetic position for artificial gingiva differs from the ideal biomechanical position. The implant axes and angulations should allow for the abutment screw to emerge lingual to the

incisal edge of the restoration, allowing for placement of a screw-retained prosthesis (Fig 6).

When fewer implants are placed, the arch is easier to restore. This allows for fewer abutments and more pontics. As long as biomechanical principles are not jeopardized, limiting the number of implants gives the ceramist more flexibility in developing the artificial gingival anatomy. It is usually easier to achieve an esthetic result with pontics than with abutments, apart from facilitating oral hygiene (Table 1).

Table 1 Recommended no. of implants and positions in the arch for prosthetic gingival reconstruction			
No. of missing teeth	No. of implants	Actual patient	Diagram
1	1		
2	1		
3	2		
4	Place 3 and use 2		
5	3		
6	Place 4 and use 3		

Implant placement away from the midline is preferable, with the anterior esthetic zone left to be restored with pontics (Table 1). When needed to facilitate ideal locations and spacing of implants, a natural tooth abutment may need to be sacrificed to place an implant.

The inclination of the implants should always be planned to allow for lingual screw access to permit fabrica-

tion of a screw-retained prosthesis. A screw-retained prosthesis will provide better control of the emergence profile, as the esthetic material can start closer to the head of the implants, allowing the ceramist to develop this profile throughout the transmucosal extension during the process of fabricating and trying in the prosthesis. A conventional cemented prosthesis emergence profile is more dependent

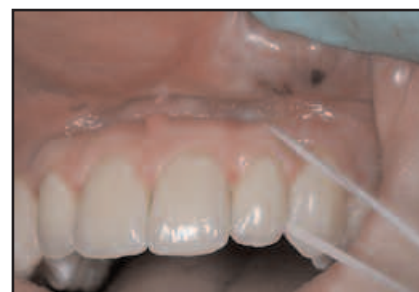

Fig 7 The patient should be able to carry out hygiene procedures if the prosthesis is designed correctly.

on the abutment, leaving almost no room for the ceramist to change the interface between the natural and artificial gingiva. Another key reason to plan for a screw-retained prosthesis is maintenance. Both hygiene access (Fig 7) and repairs are sometimes necessary. Retrieval of a restoration allows the clinician and technician to perform any necessary repairs outside the mouth.

Implant depth is a critical factor to obtain a healthy and esthetic restoration. In a conventional implant restoration, the implant should be placed 2 to 3 mm apical to the cervical limit of the crown. For an artificial gingival restoration, the implant should be placed 3 mm beyond the apical limit of the proposed artificial gingiva. The greater the horizontal tissue loss, the deeper the implant needs to be placed by the surgeon to restore a harmonious gingival profile. The apical limit of the prosthetic gingival restoration will be guided by the dental-gingival diagnostic wax-up. The wax-up will generate a "dental-gingival radiographic stent" that enables the clinician to visualize the entire restoration with the appropriate interactive 3D software after the CT scan.

The esthetic quadrant concept

The image on the computer screen will present the actual patient ridge, the ideal positions of the crowns, and the ideal profile of the artificial gingiva. Historically, these stents focused on crown and implant positioning only. The authors have originated the "esthetic quadrant plan," which brings into consideration all four aspects of the restoration: the lip zone, the hard and soft tissue in the implant-surgical zone, the visible esthetic zone, and the restorative zone (Figs 8 to 10). Virtual lines are drawn between these zones to clarify the prosthetically ideal positions of hard and soft tissue.

The intersection of the lines of the actual ridge and ideal gingiva will give an approximate location of where the

restoration will end apically (Figs 8 to 10). Three millimeters above this point should be the head of the implant. The patient's upper lip line when smiling should also be marked on the radiographic stent. Transferring this information to the screen will also enable the implant team to plan the edge of the restoration ideally to the lip line, bearing in mind the fact that the ideal situation is to hide this limit beyond the lip perimeter. In patients with very high lip lines (vertical maxillary excess), this is not always possible, thus increasing the challenge for the ceramist. The image on the screen will also allow a better understanding of the necessity of other procedures such as bone grafts and ridge reshaping. Bone grafts, in these situations, are directed mostly horizontally, with bone reduction vertically and gingival reshaping often needed to flatten the surface of the ridge receptor area. This will provide more space for artificial gingiva, hide the limits of the restoration, and enable efficient hygiene procedures.

This combination of grafts and correct depth of implant placement by the surgeon should allow for a more ideal artificial gingival profile that is not too steep and thereby avoids food entrapment and decreased mobility of the upper lip. The angle of the artificial gingiva with the occlusal plane should not exceed 45 degrees (Figs 8 and 9).

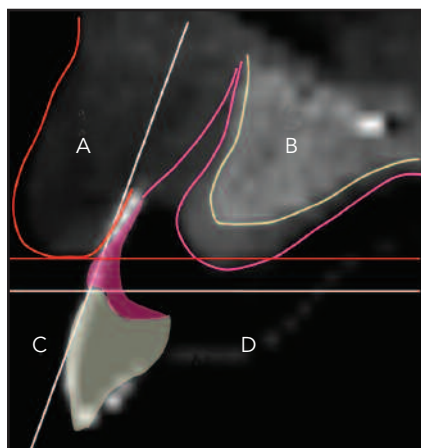


Fig 8 Two virtual lines drawn on the CT create four quadrants: the lip zone (A), the hard and soft tissue and implant-surgical zone (B), the visible esthetic zone (C), and the restorative zone (D). The ideal position of the buccal surface of the crown and gingival margin will generate the vertical line. The cemento-enamel junction of the central incisor will establish the horizontal line. The red line corresponds to the lip line when smiling. In the first step of restoring this patient, the bone and soft tissue graft should be planned to bring the ridge forward toward the vertical line, filling in the B quadrant but not invading A.

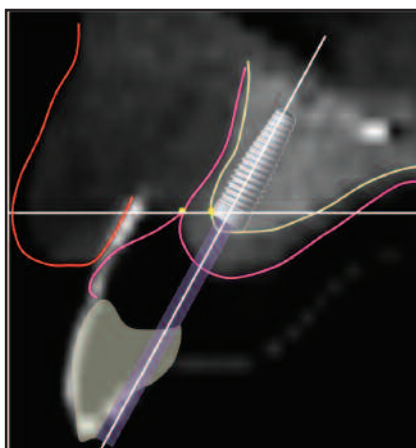


Fig 9 The profile of the artificial gingiva, when touching the natural gingiva, will create a point. A horizontal line (implant depth line) that extends over this point will establish another point on the bone. This will establish the ideal depth of the head of the implant. The axis of the implant will be determined by the vertical line that allows for lingual screw access. The intersection of these two lines will determine the ideal 3D position of the implant. In the present patient, the crest of the ridge that is under the horizontal line should be reduced, creating a flat surface (ridge reduction). The head of the implant is then placed level to the horizontal line, with the axis toward the cingulum of the crown. The implant should not invade quadrant D to avoid an unhealthy ridge lap. This planning should allow for a healthy and esthetic interface between natural and artificial gingiva.

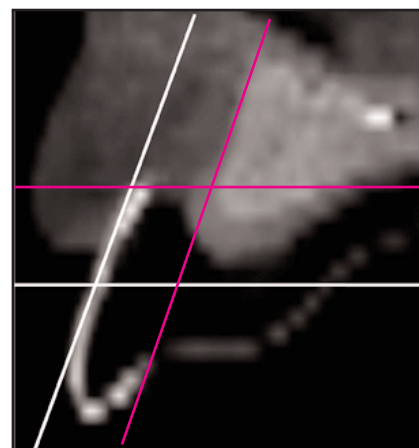
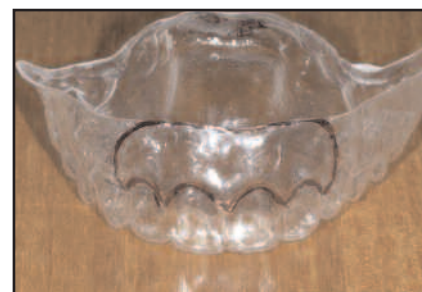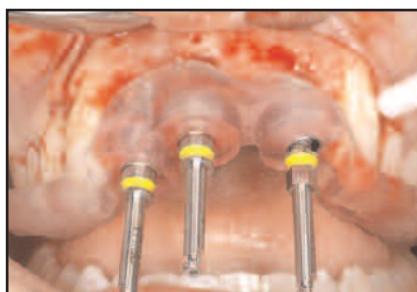
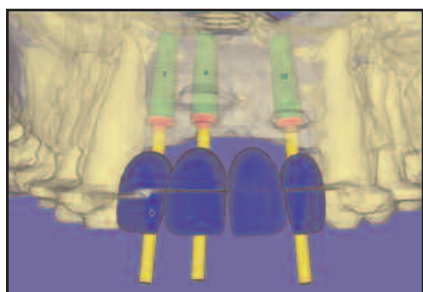


Fig 10 Radiographic image showing the radiographic stent that provides the clinicians with the ideal buccal profile of the crown and gingiva. The same lines shown in Figs 8 and 9 are used to plan the artificial gingival shape, grafts, bone reshaping, and implant position. White lines create the four quadrants; red lines establish the 3D position of the implant.

This protocol vastly changes the existing paradigm. In contrast to traditional site development, which is aimed at the addition of hard and soft tissues for esthetics, the surgical team would focus their efforts on interface development; they would seek to optimize the position of the tissue-restoration interface relative to the lip line when artificial gingiva reconstruction is needed (Figs 8 to 10).

All this should be analyzed early, during the diagnostic stage. The

authors note that most cases of anterior teeth and tissue loss are currently designed for surgical grafting first, followed by implant placement later, without ever considering artificial gingiva as an original treatment option. This new perspective, may in fact, limit the amount of surgical failures and misadventures that patients currently undergo, as well as minimizing cost, overall treatment time, and patient discomfort.



Figs 11 and 12 The 3D software generates the information to fabricate the surgical stent.

Fig 13 Dental-lingual stent generated from the wax-up. The line that represents the apical margin of the future artificial gingiva will guide the depth of implant placement and any needed bone reduction.

Surgery for artificial gingiva

Implant placement should closely follow the dental-lingual waxup and surgical stent. The surgical stent will guide the axis of the implant, and the dental-lingual stent will guide the depth of placement (Figs 9 and 10). From a surgical standpoint, it is preferable to place the implants deeper in the bone, with the goals of lingual screw access and as many pontics as possible (based upon sound biomechanical

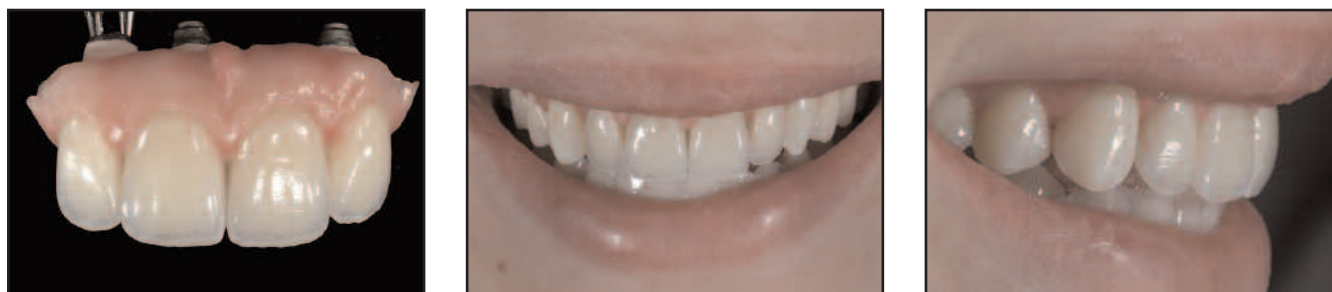principles) rather than multiple adjacent abutments.

Following the same surgical philosophy mentioned earlier, the ridge width needs to be restored more horizontally and less vertically. In contrast to the classic goals of most implant surgeons, who attempt to reestablish interproximal vertical support for the papilla, bone reduction or reshaping is often necessary with artificial gingiva to create a flat ridge between the implants. This will help create an

esthetic and cleansable relationship between the natural ridge and the pontics.

All these procedures are planned and determined precisely with the 3D software simulation surgery (Figs 11 to 13).

Grafts that seek to establish the optimal foundation for an artificial gingival restoration should mainly gain volume horizontally. Vertical increases in volume hinder the esthetic result in most instances. From



Figs 14 to 16 The prosthetic gingival restoration over multiple implants reestablishes both white and pink esthetics. Notice how important the presence of the artificial papillae is in creating harmony among natural and artificial teeth and lips.

an esthetic standpoint, this provides a higher degree of predictability, as most often it is the vertical dimension that cannot be predictably recreated surgically in conventional implant tooth replacement.

Psychologic factors are very relevant to the present treatment. As mentioned earlier, the patient may have a negative predisposition toward artificial gums. This makes the presentation of the case a most important step. The approach needs to be supported by technical information, followed by visual examples. The authors normally guide the patient in relation to the complexity of the case, the esthetic limits, advantages and disadvantages. Advantages include fewer surgical procedures, more predictable pink esthetics, and decreases in the time and costs of overall treatment. However, patients may show resistance to artificial gums. Also, to develop the artificial gingiva, a framework that will join all the implant abutments must be created, so that routine flossing is impossible. More delicate hygiene will be required for some patients.

Conclusion

The use of digital images, diagnostic wax-ups, and demonstrative artificial gingival prostheses helps patients overcome the initial psychologic barrier, and they become more likely to accept the treatment. Patients with a low lip line are naturally most appropriate, since they will not display the transition between natural and artificial gingiva. Patients with unfavorable diagnostic indicators and guarded predictability in relation to the success of necessary surgical augmentation procedures should be made aware of the potential of prosthetic gingival restoration in addition to the various conventional therapies (Figs 14 to 16).

In part 3 of this series the authors will discuss the laboratory procedures, clinical procedures, and maintenance of these types of prostheses.

References

1. Garber DA. The esthetic dental implant: Letting restoration be the guide. *J Am Dent Assoc* 1995;126(3):319–325.
2. Salama H, Salama MA, Garber D, Adar P. The interproximal height of bone: A guidepost to predictable aesthetic strategies and soft tissue contours in anterior tooth replacement. *Pract Periodontics Aesthet Dent* 1998;10(9):1131–1141.
3. Salama H, Salama MA, Garber D, et al. Lessons from periodontal prosthesis: 50 years of site development. *J Esthet Dent* 1998;10(3):149–156.
4. Saadoun AP, LeGall M, Touati B. Selection and ideal three-dimensional implant position for soft tissue aesthetic. *Pract Periodontics Aesthet Dent* 1999;11(9):1063–1072.
5. Kois JC. Predictable single tooth peri-implant esthetics: Five diagnostic keys. *Compend Contin Educ Dent* 2001;22(3):199–206.
6. Tarnow DP, Magner AW, Fletcher P. The effect of distance from the contact point to the crest of bone on the presence or absence of the interproximal dental papilla. *J Periodontol* 1992;63(12):995–996.
7. Duncan JD, Swift Jr E. Use of tissue-tinted porcelain to restore soft-tissue defects. *J Prosthodont* 1994;3(2):59–61.
8. Barzilay I, Tamblyn I. Gingival prosthesis – A review. *J Can Dent Assoc* 2003;69(2):74–78.
9. Hannon SM, Colvin CJ, Zurek DJ. Selective use of gingival-toned ceramics: Case reports. *Quint Int* 1994;25(4):233–238.
10. Rosa DM, Souza Neto J. Odontologia estética e a Prótese fixa dentogengival – Considerações cirúrgicas e protéticas – Casos clínicos e laboratoriais: uma alternativa entre as soluções estéticas. *J Assoc Paul Cir Dent* 1999;53(4):291–296.
11. Rosa DM, Zardo CM, Souza Neto J. Prótese fixa metalo-cerâmica dento-gengival: Uma alternativa entre as soluções estéticas. São Paulo: Artes Médicas, 2003.
12. Hayakawa I. Principles and Practices of Complete Dentures: Creating the Mental Image of a Denture. Tokyo: Quintessence, 2001.
13. Ganz SD. Presurgical planning with CT-derived fabrication of surgical guides. *J Oral Maxillofacial Surg* 2005;63(9 suppl 2):59–71.